

# Optical Coherence Tomography Findings in Myopic Traction Maculopathy

Giacomo Panozzo, MD; Andrea Mercanti, MD

**Objective:** To describe the features and incidence of epiretinal traction and related retinal damage in degenerative myopia.

**Design:** Consecutive observational case series.

**Methods:** We retrospectively reviewed medical records and optical coherence tomography findings of 218 eyes with high myopia of 121 consecutive patients to detect the incidence and features of epiretinal traction-related macular damage. The degree of myopia ranged from  $-8$  to  $-26$  spherical equivalent (mean  $\pm$  SD,  $-16.93 \pm 5.74$ ). Mean  $\pm$  SD axial length was  $29.75 \pm 2.12$  mm. Excluding eyes with possibly confounding features, 125 eyes were analyzed.

**Main Outcome Measure:** Detection of epiretinal traction and related macular damage.

**Results:** Epiretinal traction was found in 58 (46.4%) of 125 eyes and retinal damage, in 43 eyes (34.4%). Macular retinoschisis was the most frequent form of macular damage (25 eyes [58%]), followed by retinal thickening, lamellar hole, and shallow retinal detachment.

**Conclusions:** Epiretinal traction is a frequent finding in degenerative myopia and, particularly if associated with the presence of staphyloma, can generate a form of macular damage unique to eyes with high myopia. This damage can affect up to one third of these eyes and should be considered as a separate cause of visual loss easily detected by optical coherence tomography at its early stages.

*Arch Ophthalmol.* 2004;122:1455-1460

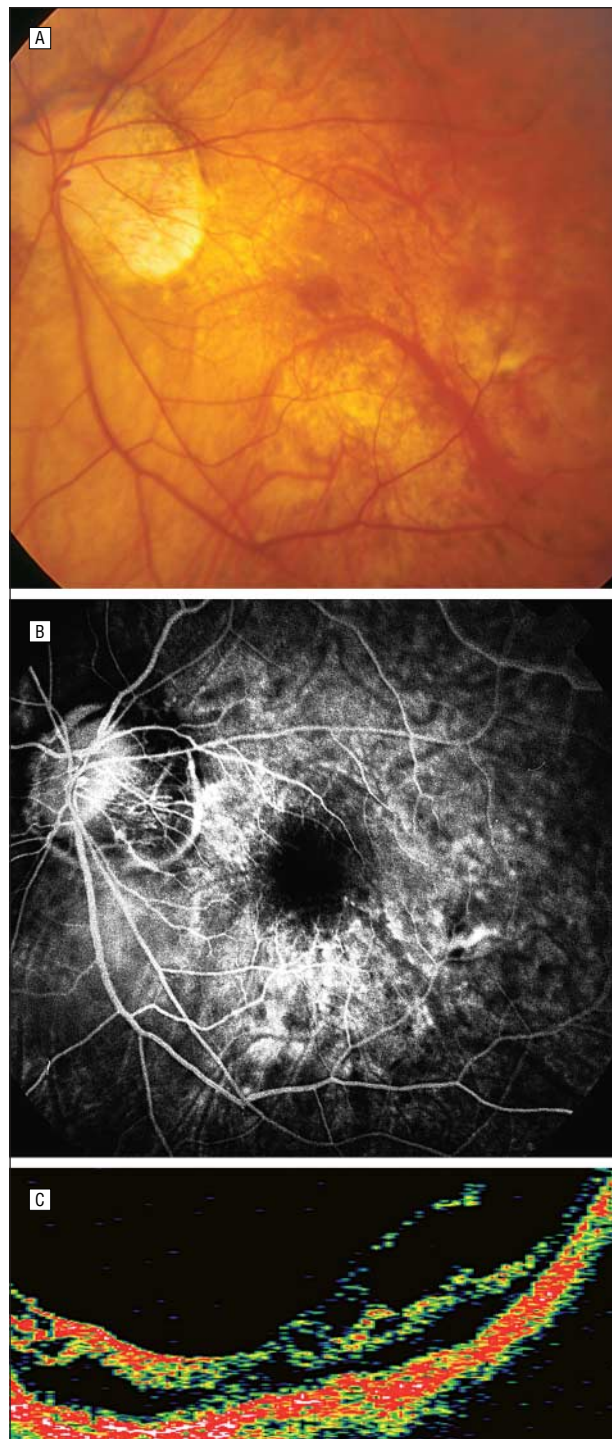
**D**EGENERATIVE MYOPIA, also called pathologic or high myopia, is defined as a myopic refractive error of more than 6 diopters associated with degenerative fundus changes.<sup>1</sup> The main feature of degenerative myopia is a congenital scleral weakness leading to progressive globe enlargement, axial lengthening, and finally the formation of posterior staphyloma. Following this scleral stretching, degenerative changes such as progressive atrophy of the choriocapillaris and choroid, linear ruptures of the Bruch membrane (lacquer cracks), and retinal thinning can occur. Other typical features of degenerative myopia are vitreous degeneration and high frequency of peripheral retinal lesions such as lattice degeneration and retinal tears. As a result of all these degenerative processes, eyes with high myopia are at increased risk of visual impairment from rhegmatogenous retinal detachment, progressive chorioretinal atrophy, choroidal neovascular membrane, spontaneous fo-

veal hemorrhage, rupture of the Bruch membrane, and macular hole with or without posterior retinal detachment.

Apart from these causes of visual loss in eyes with high myopia, the posterior retina can also be damaged by the presence of traction induced by the epiretinal membrane (ERM) and/or residual focal vitreoretinal adhesion (vitreomacular traction [VMT]), which in these eyes is combined by the distinctive presence of posterior staphyloma and progressive global scleral stretching. This unique combination of retinal traction generated by ERM and/or VMT mixed with the complex and distinctive anatomy of degenerative myopia leads to the frequent presence in these eyes of macular damage such as retinoschisis, lamellar holes, or shallow detachment<sup>2</sup> and may also play an important role in the pathogenesis of macular hole formation and posterior retinal detachment.

We propose to unify all these pathologic features generated by traction in the myopic environment under the name of *myopic traction maculopathy* (MTM).

From TECLO srl, Vitreoretinal Service, Verona, Italy. The authors have no relevant financial interest in this article.



**Figure 1.** A patient, aged 71 years, with  $-19$  spherical equivalent OS and a progressive decrease in visual acuity in the last 16 months from 20/40 to 20/200. A, Color fundus photograph showing absence of atrophy or Fuchs spot. Media were completely clear. B, Fluorescein angiogram showing absence of choroidal neovascularization. C, Optical coherence tomography demonstrates retinal traction with schisis and shallow retinal detachment.

Because of the characteristic and confounding features of the choroid, retina, and vitreoretinal interface in degenerative myopia (ie, tigroid fundus, thin retina, areas of choriocapillaris atrophy, retinal pigment epithelium hypopigmentation and/or hyperpigmentation, posterior staphyloma, etc), the early stages of traction maculopa-

thy can be easily underestimated by biomicroscopy, angiography, or ultrasonography, and consequently, its presence can remain undiagnosed.

Optical coherence tomography (OCT) with cross-sectional images of retinal structure greatly facilitates the study of the posterior vitreoretinal anatomy in eyes with high myopia and allows the detection of subtle macular changes that are otherwise undetectable (**Figure 1**).

The purpose of this study is to describe the incidence and features of macular abnormalities related to traction in a healthy population of 121 patients with eyes with high myopia analyzed by OCT.

## METHODS

From April 2001 to May 2002, we examined with OCT all the eyes of all patients with high myopia who came to us for routine examination. Patients in the study could be asymptomatic or have vision loss. We examined 218 eyes of 121 consecutive patients, 41 men (33.88%) and 80 women (66.12%) with a mean  $\pm$ SD age of  $59.24 \pm 14.99$  years (median, 59 years). The degree of myopia ranged from  $-8$  to  $-26$  spherical equivalent (mean  $\pm$ SD,  $-16.93 \pm 5.74$ ; median,  $-17.5$ ). The mean  $\pm$ SD axial length was  $29.75 \pm 2.12$  mm.

All eyes had 1 or more chorioretinal features typical of degenerative myopia (ie, tigroid fundus, stretched vascular arcades, peripapillary and chorioretinal atrophy, posterior staphyloma, and lacquer cracks). Prior to OCT scan, each eye underwent a complete ophthalmic evaluation.

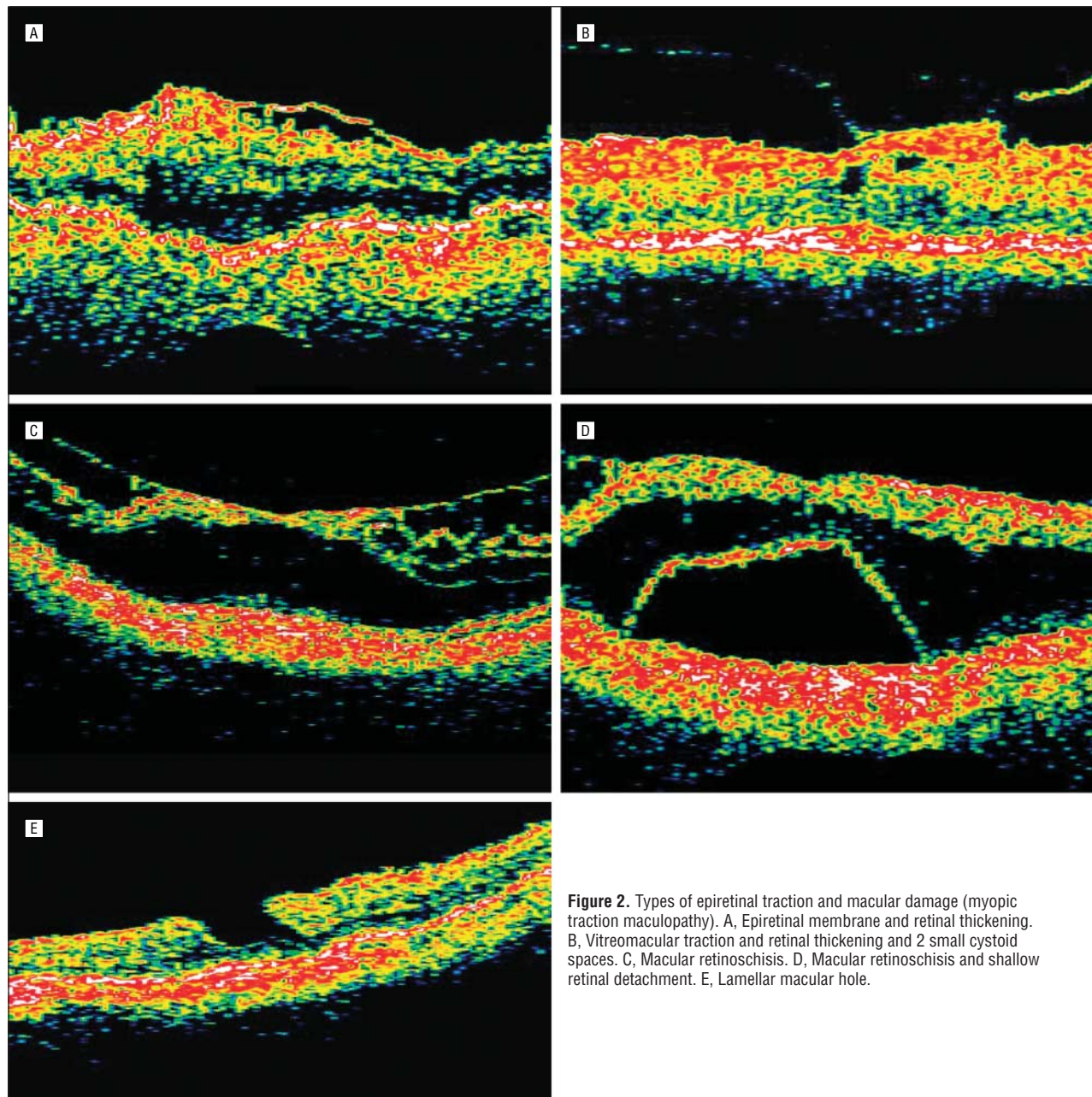
All patients obtained and signed an informed consent prior to examination. Institutional review board approval was not requested for this study.

Because the major goal of this study was to investigate in a healthy myopic population the presence of epiretinal and/or vitreoretinal traction and related macular damage, we excluded from analysis all eyes with possible confounding features such as concomitant ophthalmic pathologic conditions other than myopia and eyes with Fuchs spots, active choroidal neovascularization (determined by fluorescein angiography), or acute visual loss for posterior or diffuse retinal detachment visible at biomicroscopy. Eyes with pseudophakia that had or had not undergone Yag laser capsulotomy or eyes that had undergone peripheral laser or cryopexy treatments were included. A total of 125 (55.5%) of 218 eyes were analyzed.

Among this "healthy" myopic population, we considered patients as symptomatic if they described in 1 or 2 eyes a "worsening" in visual function in the last 6 months. We defined this worsening as increased metamorphopsia with a decrease in visual acuity equal to or greater than 2 lines on a Snellen chart, unexplained by media opacities or changes on fluorescein angiography. Patients were considered asymptomatic if they described stable vision for at least 2 years or minimal recent changes. Any previous peripheral laser or cryopexy treatment was recorded.

Optical coherence tomography (Zeiss-Humphrey, San Leandro, Calif), based on the principle of low-coherence interferometry, provides cross-sectional images of ocular structures and measurement of retinal thickness with a resolution of  $10 \mu\text{m}$ . This resolution is superior to other imaging techniques such as scanning laser ophthalmoscopy ( $300\text{-}\mu\text{m}$  resolution), B-mode ultrasonography ( $150\text{-}\mu\text{m}$  resolution), and ultrasound biomicroscopy ( $20\text{-}\mu\text{m}$  resolution).<sup>3</sup>

The same observer (A.M.) performed all OCT examinations. We tried to optimize OCT imaging by obtaining maximal pupil dilation and maintaining a good tear film with frequent blinking or with application of artificial tears.



**Figure 2.** Types of epiretinal traction and macular damage (myopic traction maculopathy). A, Epiretinal membrane and retinal thickening. B, Vitreomacular traction and retinal thickening and 2 small cystoid macular spaces. C, Macular retinoschisis. D, Macular retinoschisis and shallow retinal detachment. E, Lamellar macular hole.

We used the following OCT scanning techniques:

1. Two 3-mm “line group” scans, centering the fovea, at 0° and 90°.
2. Two 7-mm line group scans, one vertical centered on the fovea and the other starting from the optic disc to the fovea, to explore the borders of the staphyloma (when present).
3. Six 6-mm “radial lines” scans centered on the fovea, 1 scan every 30°, for complete evaluation of the posterior pole.

The analysis of OCT images was focused on the presence of epiretinal traction and on changes in retinal structure.

1. Epiretinal traction was subdivided into 2 groups:
  - a. Epiretinal membrane: tangential traction from overlying ERM often with multifocal attachments (**Figure 2A**).

- b. Vitreomacular traction: anteroposterior traction from incomplete vitreomacular separation (**Figure 2B**).
2. Retinal damage was classified as follows:
  - a. Retinal thickening: foveal thickness  $>200\ \mu\text{m}$  (With OCT, the mean  $\pm$ SD nonmyopic normal adult foveal thickness is  $150 \pm 20\ \mu\text{m}$ .<sup>4-6</sup>) with or without cystoid macular changes (**Figure 2A** and **B**).
  - b. Macular retinoschisis: separation of the neurosensory retina into 2 or more layers (**Figure 2C**).
  - c. Retinal detachment: shallow neuroepithelial detachment (**Figure 2D**).
  - d. Lamellar macular hole: partial thickness macular hole (**Figure 2E**).

Each of these categories of epiretinal traction and/or intraretinal damage could be present in isolation or in combination with others. When appropriate, the data were statistically compared using a  $\chi^2$  test.

**Table 1. Summary of Results**

	No. (%) of Eyes
Sample size	125
Epiretinal traction	58 (46.4)
ERM	31 (24.8)
VMT	11 (8.8)
ERM and VMT	16 (12.8)
Retinal damage	43 (34.4)
Macular retinoschisis	25 (20.0)
Retinal thickening	10 (8.0)
Lamellar macular hole	6 (4.8)
Retinal detachment	2 (1.6)
Staphyloma	53 (42.4)

Abbreviations: ERM, epiretinal membrane; VMT, vitreomacular traction.

**Table 2. Relationship Between Retinal Damage and the Presence of Epiretinal Traction and Staphyloma\***

	Epiretinal Traction (ERM/VMT)	Epiretinal Traction and Staphyloma	Staphyloma
Retinal damage (n = 43)	16 (37.2)	20 (46.5)	7 (16.2)
Macular retinoschisis (n = 25)	8	15	2
Retinal thickening (n = 10)	6	3	1
Retinal detachment (n = 2)	1	0	0
Lamellar hole (n = 6)	1	2	4

Abbreviations: ERM, epiretinal membrane; VMT, vitreomacular traction.

\*In the first row (retinal damage), the relationship between traction maculopathy (all types) and epiretinal traction and/or staphyloma is presented. In the rows below, this relationship is specified for each type of macular damage. Values are expressed as number (%) of eyes.

**Table 3. Relationship Between Visual Symptoms and Optical Coherence Tomography (OCT) Findings\***

OCT Findings	No Symptoms	Symptoms
Normal (n = 67)	61	6
Retinal damage (n = 43)	29	14
Macular retinoschisis	15	10
Retinal thickening	9	1
Lamellar hole	5	1
Retinal detachment	0	2
Epiretinal traction (n = 15)†	12	3
<b>Total (N = 125)</b>	<b>102</b>	<b>23</b>

\*Symptomatic was defined as a patient with a worsening of at least 2 Snellen lines in visual function in the last 6 months in 1 eye. Values are expressed as number of eyes.

†Not associated with retinal damage.

## RESULTS

The results of the analyzed sample of 125 eyes are summarized in **Table 1**. Epiretinal traction was noted in 58 eyes (46.4%). The most frequent form of traction was ERM, found in 31 eyes (24.8%), while a mixed form of tangential (ERM) and anteroposterior (VMT) traction was present in 16 eyes (12.8%). Eleven eyes (8.8%) had VMT alone.

Retinal damage was present in 43 eyes (34.4%). Macular retinoschisis, isolated or associated with other lesions, was the most frequent form of damage, identified in 25 eyes (20.0%). Ten eyes (8.0%) had macular thickening, 6 eyes (4.8%) had a lamellar macular hole, and 2 eyes (1.6%) had an isolated shallow retinal detachment. In 53 (42.4%) of 125 eyes a staphyloma was present.

Retinal damage was most often associated with the presence of epiretinal traction as summarized in **Table 2**. Of 43 eyes with a form of retinal damage, 36 eyes (83.7%) had an associated epiretinal traction, isolated (16 eyes [37.2%]) or combined with staphyloma (20 eyes [46.5%]). Only 7 eyes (16.2%) with retinal damage had a posterior staphyloma without epiretinal traction. **Table 2** also presents the relationship between each form of retinal damage and the presence of epiretinal traction and/or staphyloma.

In our series, 9 eyes had previous peripheral treatment for lattice degeneration or atrophic breaks (7 laser, 2 cryopexy). Four of these eyes (3 laser, 1 cryopexy) had macular retinoschisis.

Of 121 patients (125 eyes) included in the study, 23 (19%) were judged to be symptomatic (see earlier description) in one eye. Only 6 (26.1%) of these 23 eyes had no abnormalities on OCT, while 17 (73.9%) had some macular anomalies; 14 had a form of retinal abnormality, mostly retinoschisis, and 3 had an epiretinal traction not associated with other macular lesions. On the contrary, of 43 eyes with retinal abnormalities, only 14 (32.5%) were judged symptomatic. The relationship between macular abnormalities and symptoms are summarized in **Table 3**.

## COMMENT

It is well known that myopic macular holes can be complicated by development of extensive retinal detachment.<sup>7-9</sup> This unusual natural history for macular holes is probably determined by the combination of epiretinal and/or anteroposterior traction with the unique presence of posterior staphyloma<sup>7,10-12</sup> and probably also a weak retinal pigment epithelium-photoreceptor adherence.<sup>13</sup> The clinical anatomy preceding and leading to this pathologic event has not been studied extensively.

In 1985, Green<sup>1</sup> reported in histopathologic studies of eyes with high myopia the presence of so-called stretch schisis in the peripheral retina. These studies did not identify internal membranes or focal inner retinal traction in these areas, and this retinal splitting was related to low elasticity of some retinal components, mainly blood vessels and internal limiting membrane, that cannot follow the progressive scleral stretching and elongation so pronounced in some of these eyes.

Although back in 1938, Rochon-Duvigneaud<sup>14</sup> reported similar findings in the posterior pole, it is only recently that Takano and Kishi,<sup>2</sup> using OCT, demonstrated in vivo the frequent presence of posterior retinoschisis and shallow macular detachment in eyes with degenerative myopia. Their findings were confirmed in 21 eyes by Benhamou et al.<sup>15</sup> Takano and Kishi related these findings with the formation of macular hole and hypothesized that in these eyes, posterior retinal detach-

ment precedes the formation of the hole, without speculating about the relative importance of “internal” traction combined with posterior staphyloma in the determination of posterior macular detachment in the presence of macular hole in eyes with high myopia.

In this study, we analyzed a sample of 125 eyes of 121 consecutive patients with degenerative myopia on routine examination with no symptoms or with only mild visual impairment in the last months (see earlier definition of *symptomatic*). This sample could therefore well represent a “healthy” myopic population. Using the high resolution of OCT and excluding active or fibrotic chorioidal neovascularization or other possibly confounding pathologic conditions, we looked in these eyes for the presence of early and otherwise undetectable epiretinal traction or retinal abnormalities.

The results of our study were partially unexpected; almost half of this population (58 eyes [46.4%]) revealed at OCT examination an epiretinal traction determined by ERM or VMT, and one third of eyes (43 [34.4%]) had a form of retinal damage (Table 1).

In the presence of epiretinal traction, the posterior retina in degenerative myopia lies in a peculiar and unstable condition determined by 2 opposite forces: (1) epiretinal membranes and vitreomacular adhesions generate a centripetal and/or internal traction, while (2) staphyloma and progressive scleral stretching, although not being an active form of traction, generate an external force that greatly enhances the internal traction. The retinal damage produced by this unique combination is therefore much more profound compared with the damage caused by epiretinal membranes or vitreomacular traction in eyes without myopia.

Because of the distinct features and clinically significant effect on retinal tissue and visual function, we have to consider this condition separately from the epiretinal traction syndromes found in eyes without myopia. With the purpose of unifying all the possible features of myopic macular damage from traction under a single name, we propose to call this syndrome *myopic traction maculopathy* (MTM).

Identification of the early stages of MTM is difficult with commonly available diagnostic techniques and tools. With biomicroscopy, a clear view of the vitreoretinal interface usually is precluded by the absence of a uniform retinal pigment epithelial background. The image is distorted by the posterior staphyloma and media opacities. There often are zones of chorioretinal atrophy, retinal pigment epithelial hyperplasia, or subretinal fibrosis, and the retina can be thinner than normal.

The subtle and early retinal changes generated by traction can be also invisible by stereoangiography (Figure 1) because they do not create vascular abnormalities and are also under the resolving power of ultrasonography.

With these tools, only the most advanced stages of MTM can be diagnosed, when retinoschisis cavities or neuroepithelial detachment are wide and elevated or when a macular hole with or without retinal detachment has already developed. As demonstrated by Gallemore et al,<sup>16</sup> OCT is much more sensitive than biomicroscopy in detecting subtle internal retinal changes, and especially

in the unusual and often variegated fundus photographs of eyes with degenerative myopia, OCT can greatly contribute to the fine analysis of the retinal structure through cross-sectional images with a resolution of about 10  $\mu$ m.

In our series, we found a form of retinal damage in one third of cases (43 eyes [34.4%]). The most frequent abnormality was macular retinoschisis (25 eyes), alone or associated with other lesions (Table 1). Such a high frequency of retinal damage in a myopic population corresponds to the 34% reported by Takano and Kishi<sup>2</sup> in a smaller sample (32 eyes).

In their recent report, Baba et al<sup>17</sup> divided 134 eyes with high myopia into 2 groups according with the presence or absence of staphyloma. They reported 7 cases of foveal detachment (prevalence of 9%) only in the group with staphyloma. Two of these eyes had the contemporary presence of foveal detachment and retinoschisis. In our sample of 125 eyes, we found an even smaller percentage of isolated shallow detachment, only 2 cases (1.6%), and even in our sample, both of these eyes had a posterior staphyloma. On the contrary, we report a much higher presence of retinoschisis (25 eyes [20%]), isolated or often combined with focal and shallow detachment (Table 1). Of these 25 eyes, 17 (68%) had a posterior staphyloma, and 7 (32%) had only a form of epiretinal traction. This difference may be partially related to some differences in judgment regarding the presence or absence of staphyloma, sometimes arbitrary in these very long eyes, or to the interpretation of the OCT scan. In our sample, retinoschisis had a much higher prevalence, and we have no explanation for this difference.

Only about one third of macular abnormalities found in our sample were associated with symptoms (Table 3), probably because visual impairment in eyes with myopia is multifactorial and these lesions may represent a chronic condition. In almost all the patients who had a progressive decrease in visual function unexplained by media opacities or changes in fluorescein angiography, we found a form of macular damage or epiretinal traction (Table 3).

Although it is possible other factors contributed to the cause of visual impairment in addition to MTM (amblyopia, chorioretinal atrophy, lacquer cracks, etc), the results of this study suggest that MTM should be considered a frequent abnormality in degenerative myopia and a possible cause of decreasing visual function.

Almost half the eyes in this study (58 [46.4%]) revealed at OCT a form of epiretinal traction in the macular area, tangential (ERM) and/or anteroposterior (VMT) to the inner retinal surface. This unexpected high frequency of epiretinal traction is higher than in eyes without myopia. Although in our series a posterior staphyloma was present in 53 eyes, just 7 (16.2%) of the 43 eyes with retinal damage were only associated with staphyloma, and 36 of these eyes (83.7%) were associated with the presence of epiretinal traction, isolated or in combination with a staphyloma. These findings suggest that this form of retinal damage is mainly related to epiretinal tractional forces and then enhanced by the presence of staphyloma and retinal stretching due to progressive scleral elongation.

Polito et al<sup>18</sup> in their recent case report support this hypothesis, describing the resolution of retinoschisis in an eye with myopia following spontaneous vitreofoveal separation.

This study does not give information about the natural history of MTM, but from observation of some patients with bilateral myopia who had a stable macular retinoschisis in one eye and a macular hole with posterior retinal detachment in the fellow eye, we can speculate that in degenerative myopia, macular holes and MTM could represent 2 possible evolutions of the same tractional disorder, depending on depth, width, and shape of staphyloma and degree of tangential or anteroposterior traction.

The results of our study and the relationships between retinal damage and epiretinal traction seem to indicate that in the case of symptomatic patients, vitrectomy may have a positive effect on vision by releasing this traction, stopping the progression of macular damage such as retinoschisis, and possibly reducing or eliminating shallow posterior retinal detachment.

In summary, in this large case series, we demonstrated that retinal abnormalities in the macular area can be a frequent finding in eyes with degenerative myopia. Epiretinal traction probably plays a major role in this condition, especially if combined with staphyloma. Optical coherence tomography can greatly contribute in the examination of eyes with high myopia and may even show abnormalities in asymptomatic cases.

Accepted for publication May 27, 2004.

Correspondence: Giacomo Panozzo, MD, Via del Perlar 2, 37135 Verona, Italy (g.panozzo@iol.it).

- Green WR. Retina, myopia. In: Spencer WH, ed. *Ophthalmic Pathology: An Atlas and Textbook*. Vol 2. 4th ed. Philadelphia, Pa: WB Saunders; 1996:913-924.
- Takano M, Kishi S. Foveal retinoschisis and retinal detachment in severely myopic eyes with posterior staphyloma. *Am J Ophthalmol*. 1999;128:472-476.
- Hee MR, Izatt JA, Swanson EA, et al. Optical coherence tomography of human retina. *Arch Ophthalmol*. 1995;113:325-332.
- Baumal CR. Clinical applications of optical coherence tomography. *Curr Opin Ophthalmol*. 1999;10:182-188.
- Sourdille P, Santiago PY. Optical coherence tomography of macular thickness after cataract surgery. *J Cataract Refract Surg*. 1999;25:256-261.
- Hee MR, Puliafito CA, Wong C, et al. Quantitative assessment of macular edema with optical coherence tomography. *Arch Ophthalmol*. 1995;113:1019-1029.
- Morita H, Ideta H, Ito K, Yonemoto J, Sasaki K, Tanaka S. Causative factors of retinal detachment in macular holes. *Retina*. 1991;11:281-284.
- Phillips CI, Dobbie JG. Posterior staphyloma and retinal detachment. *Am J Ophthalmol*. 1963;55:332-335.
- Abdel-Latif S. Macular hole with central retinal detachment in high myopia with posterior staphyloma. *Br J Ophthalmol*. 1969;53:62-63.
- Gonvers M, Machermer R. A new approach to treating retinal detachment with macular hole. *Am J Ophthalmol*. 1982;94:468-472.
- Stirpe M, Michels RG. Retinal detachment in highly myopic eyes due to macular holes and epiretinal traction. *Retina*. 1990;10:113-114.
- Kokame GT. Early stage of macular hole in severely myopic eye. *Am J Ophthalmol*. 1995;119:240-242.
- Negi A, Marmor MF. Quantitative estimation of metabolic transport of subretinal fluid. *Invest Ophthalmol Vis Sci*. 1986;27:1564-1568.
- Rochon-Duvigneaud M. Déformation et lésions de l'œil myope: in Mawas J, introduction à l'étude de la myopie et des chorio-rétinites myopiques. *Bulletin de la Société d'Ophtalmologie de Paris*. 1938;1:1-10.
- Benhamou N, Massin P, Haouchine B, Erginay A, Gaudric A. Macular retinoschisis in highly myopic eyes. *Am J Ophthalmol*. 2002;133:794-800.
- Gallemore RP, Jumper MJ, McCuen BW, Jaffe GJ, Postel EA, Toth CA. Diagnosis of vitreoretinal adhesions in macular disease with optical coherence tomography. *Retina*. 2000;20:115-120.
- Baba T, Ohno-Matsui K, Futagami S, et al. Prevalence and characteristics of foveal retinal detachment without macular hole in high myopia. *Am J Ophthalmol*. 2003;135:338-342.
- Polito A, Lanzetta P, Del Borrello M, Bandello F. Spontaneous resolution of a shallow detachment of the macula in a highly myopic eye. *Am J Ophthalmol*. 2003;135:546-547.